

Orthodontic treatment for a patient with a unilateral cleft lip and palate and congenitally missing maxillary lateral incisors and left second premolar

Kiyoshi Tai,^a Jae Hyun Park,^b Sakiko Okadakage,^c Shingo Mori,^d and Yasumori Sato^c
Mesa, Ariz, and Okayama, Japan

Treatment of a patient with a cleft lip and palate can be challenging. A woman, aged 26 years 8 months, was referred for orthodontic evaluation of her anterior crossbite. She was unhappy with the unesthetic appearance of her maxillary anterior teeth, which were behind her mandibular anterior teeth. She had a unilateral cleft lip and palate and had received primary lip repair and palatoplasty when she was younger, as well as rhinoplasty and a secondary lip repair when she was 15. At the pretreatment evaluation, she had a concave profile with an overjet of –9 mm, a Wits appraisal of –3.8 mm, and a transposed ectopic maxillary right canine. She was treated with orthodontic treatment alone, without orthognathic surgery. The posttreatment records 9 years later showed excellent results with good occlusion, facial balance and harmony, and long-term stability. (*Am J Orthod Dentofacial Orthop* 2012;141:363-73)

Clefts of the lip and palate occur in about 1 in 700 live births in the United States and are the fourth most common craniofacial birth defect. Compared with the incidence rate reported from other countries, the frequency of all forms of clefts is somewhat higher in Asian people than in other races.¹ Not only does the incidence vary between different races, but also the prevalence of cleft type varies by sex. Clefts are caused by failure of fusion between the medial nasal process and the maxillary process, or between the palatal processes. These failures are the combined result of genetic and environmental factors.² In cleft patients, dental abnormalities such as hypodontia, malformation, and abnormal eruption pattern occur frequently.³⁻⁷

The high prevalence of congenitally missing maxillary lateral incisors is due to a deficiency in the blood supply near the cleft, either congenitally or as a result of surgery,⁸ or a deficiency in the mesenchymal support to the maxillary lateral incisor near the cleft.^{8,9} Because a deficiency of the mesenchyme can lead to insufficient mesenchymal support to the bud of the maxillary lateral incisor, cleft patients with a severe deficiency of mesenchymal mass could have congenitally missing maxillary lateral incisors.¹⁰

Timing and sequencing of orthodontic care for cleft patients can be divided into developmental periods, which are defined by age and dental development and should be considered as time frames in which to accomplish specific objectives.

The purpose of this article is to report the treatment of a woman who had a unilateral cleft lip and palate plus congenitally missing maxillary lateral incisors and a left second premolar. The patient was treated with orthodontics alone; no orthognathic surgery was performed.

DIAGNOSIS AND ETIOLOGY

A Japanese woman, aged 26 years 8 months, was referred to an orthodontist for evaluation of her anterior crossbite. Her chief complaint was the unesthetic appearance of her maxillary anterior teeth, which were behind her mandibular anterior teeth. She had a unilateral

^aVisiting adjunct assistant professor, Postgraduate Orthodontic Program, Arizona School of Dentistry & Oral Health, A. T. Still University, Mesa, Ariz; private practice, Okayama, Japan.

^bAssociate professor and chair, Postgraduate Orthodontic Program, Arizona School of Dentistry & Oral Health, A. T. Still University, Mesa, Ariz; international scholar, Graduate School of Dentistry, Kyung Hee University, Seoul, Korea.

^cPrivate practice, orthodontics, Okayama, Japan.

^dPrivate practice, general dentistry, Okayama, Japan.

The authors report no commercial, proprietary, or financial interest in the products or companies described in this article.

Reprint requests to: Dr. Jae Hyun Park, 5835 E. Still Circle, Mesa, AZ 85206; e-mail, JPark@atsu.edu.

Submitted, March 2010; revised and accepted, April 2010.

0889-5406/\$36.00

Copyright © 2012 by the American Association of Orthodontists.

doi:10.1016/j.ajodo.2010.04.037

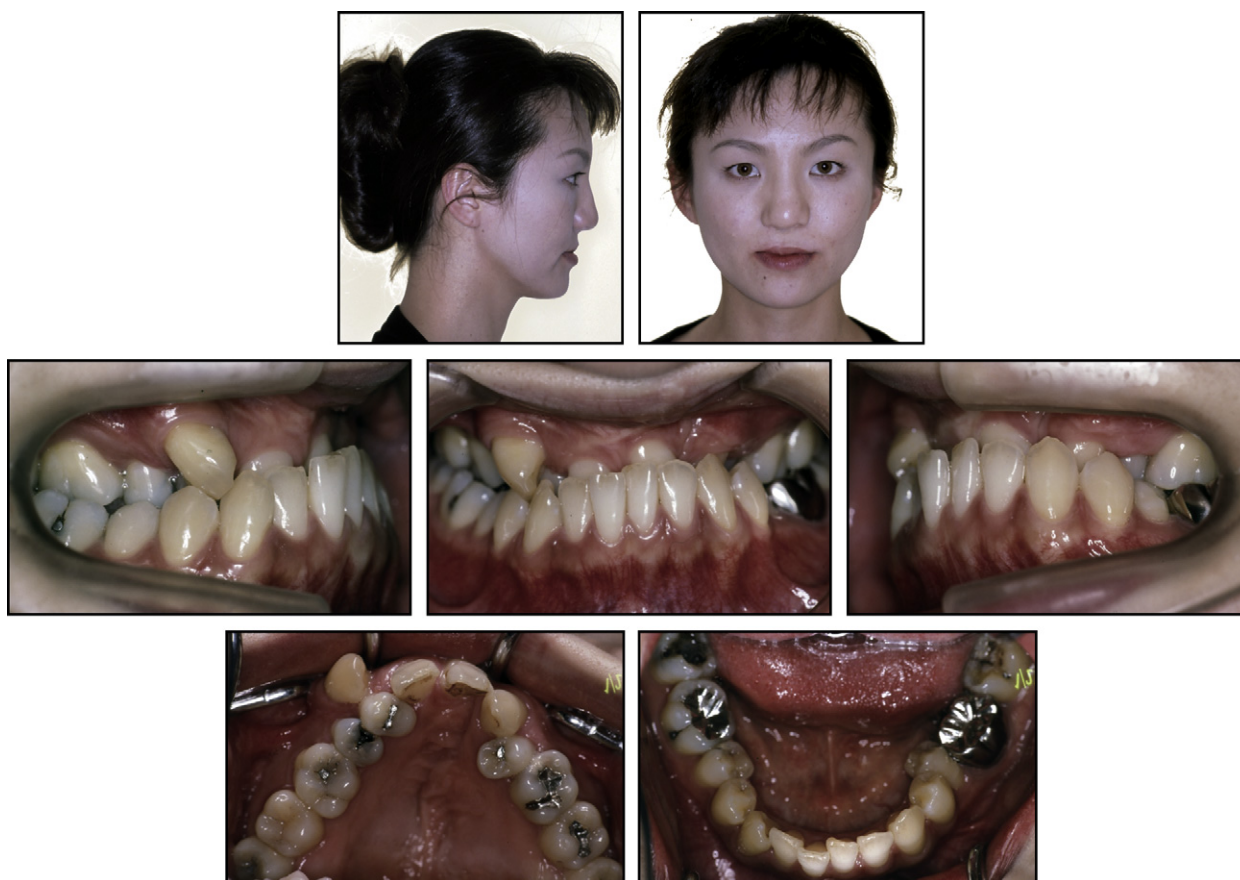

Fig 1. Pretreatment facial and intraoral photographs.

cleft lip and palate. She had received primary lip repair and palatoplasty, but she could not remember when her operation had been performed. She also had a history of rhinoplasty and a secondary lip repair when she was 15. The patient had a mesofacial and concave profile with a retrusive upper lip and maxilla. Her frontal facial photograph and posteroanterior cephalogram showed a flat alar base and a deviated nasal septum without facial asymmetry (Figs 1-3).

She was congenitally missing her maxillary lateral incisors and a left second premolar. The maxillary arch constriction was due to the unilateral cleft lip and palate. She also had severe crowding in the maxillary arch with anterior and posterior crossbites, and moderate crowding in the mandibular arch with a severe curve of Spee. She had a Class II molar relationship on both sides with an overjet of -9 mm and an overbite of 90%. The maxillary right canine was erupted in an ectopic position. The maxillary left first premolar was rotated 180° . Deep caries was present in the maxillary right second premolar, and secondary caries was developing in the mandibular right first molar and second molar. The

maxillary dental midline was deviated to the left by 2 mm relative to the facial midline. It was hard to guide the mandible into centric relation because of the significant arch-size discrepancies.

Cephalometric analysis indicated a skeletal Class III relationship (ANB, -4.7° ; Wits appraisal, -3.8 mm) with a normal growth pattern (SN-MP, 35.5°). The maxillary incisors were slightly proclined (U1 to SN, 109.5°), and the mandibular incisors showed retroclination (IMPA, 81.0°) (Fig 3, A; Table).

The panoramic radiograph showed that the crown of the mandibular left third molar was overlapping the distal root of the mandibular left second molar. The ectopic canine had a transposed root with the maxillary right first premolar (Fig 3, C).

TREATMENT OBJECTIVES AND ALTERNATIVES

The treatment objectives were to obtain normal overjet and overbite, establish a Class I canine relationship, maintain a Class II molar relationship, correct the midline shift, relieve the crowding in both arches, and level the

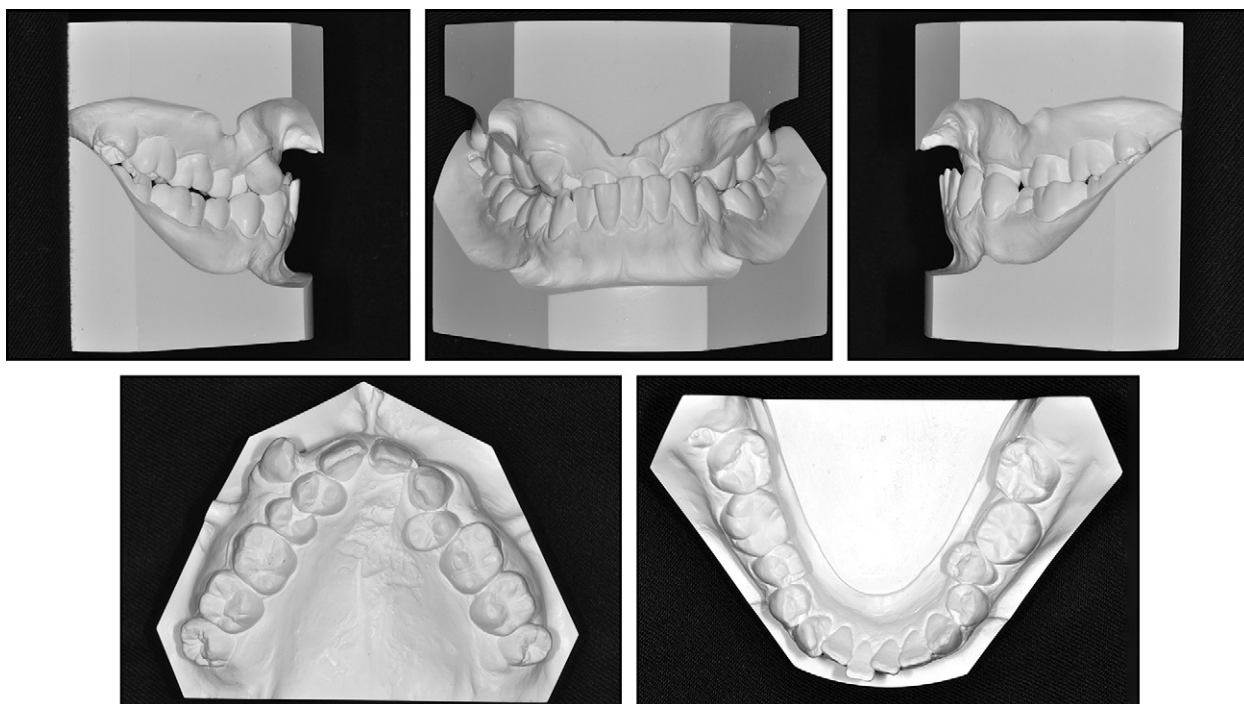


Fig 2. Pretreatment dental casts.

curve of Spee. In addition to better occlusion, improvement of the patient's profile was also crucial. Careful observation of the maxilla was required during treatment because she had had surgical lip repair and palatal closure.

To accomplish these objectives, forward movement of the premaxilla was planned, followed by lateral expansion of the buccal dentition. It was expected that her facial profile would improve after these treatments. Lip and nose revisions were also considered. It was presumed that the labial and lateral expansions would enlarge the maxillary left alveolar cleft, so a secondary bone graft was considered to close these clefts at an appropriate stage, but the patient declined the procedure. A conventional fixed prosthesis or a dental implant was planned for the missing tooth after the orthodontic treatment.

As a treatment alternative, orthognathic surgery without intensive maxillary arch expansion was considered. This plan would correct the crossbite and improve the facial profile. Using conventional orthognathic surgery techniques for patients with severe maxillary hypoplasia, surgeons would advance the maxilla as much as possible in the presence of the scar tissues from the lip and palate repairs. The remaining skeletal discrepancy would be corrected with a mandibular setback. Essentially, this would be a surgical camouflage of the inability

to correct the underlying maxillary hypoplasia predictably. Additionally, the velopharyngeal mechanism could be compromised by maxillary advancement, especially if a pharyngeal flap was used to improve speech.

Details of these alternatives were presented to the patient; however, she declined the surgery. Because of this, we decided on orthodontic treatment alone. We expected that expansion of the maxillary arch at her age would help to correct the posterior crossbite mostly by buccal tipping. Opening the space for the maxillary left lateral incisor would be helpful to expand the premaxilla. We planned to consider orthognathic surgery later, if the results of orthodontic treatment were not acceptable.

TREATMENT PROGRESS

Before orthodontic treatment, the patient was referred to a specialist for a restorative dentistry consultation including advice on how to treat the maxillary left lateral incisor. Also, she was referred to a specialist for evaluation of her existing periodontal conditions, which included the alveolar cleft area. This region showed thin attached gingivae labial to the maxillary right canine and the mandibular anterior teeth, as well as an unesthetic gingival contour of the maxillary central incisors. She was referred to an oral surgeon to evaluate her third molars.

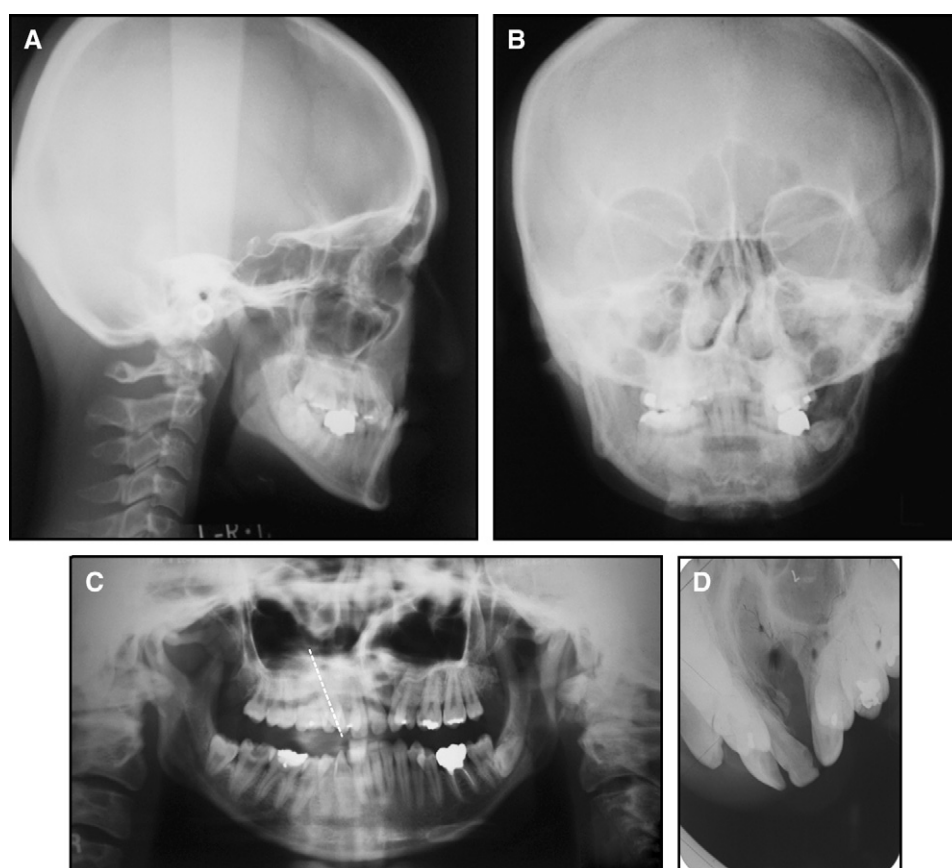


Fig 3. Pretreatment radiographs: **A**, lateral cephalogram; **B**, posteroanterior cephalogram; **C**, panoramic radiograph; **D**, occlusal radiograph. The ectopic maxillary right canine had a transposed root with the maxillary right first premolar.

Because of the positioning of the mandibular left third molar and the involvement of the distal root of the second molar, the oral surgeon recommended extraction of the latter. The mandibular left third molar could not be extracted because of its proximity to the inferior alveolar nerve. The mandibular right third molar and left second molar were extracted to upright the posterior teeth with multi-loop edgewise archwire therapy.^{11,12} The patient declined to have the maxillary third molars extracted.

A Porter-type slow expansion appliance was used to expand the maxillary arch laterally with a jumping plate on the mandibular arch. After carefully observing the response of the maxilla, full fixed 0.022-in tip-edge appliances (TP Orthodontics, LaPorte, Ind) were placed in the maxillary arch after 1 month of expansion. To prevent proclination of the mandibular anterior teeth, the fixed appliances were not placed on the mandibular arch until the anterior crossbite had been corrected. To correct the anterior crossbite, 0.016-in Australian

Table. Cephalometric measurements

Measurement	Japanese		9 years	
	norm	Pretreatment	Posttreatment	posttreatment
SNA (°)	82.3	74.8	76.0	73.7
SNB (°)	78.9	79.5	77.5	77.1
ANB (°)	3.4	-4.7	-1.5	-3.4
Wits (mm)	0.0	-3.8	-1.4	-2.8
SN-MP (°)	40.2	35.5	38.0	37.0
FH-MP (°)	28.8	26.6	29.0	27.8
LFH (ANS-Me/ N-Me) (%)	55.0	55.0	58.0	57.0
U1 to SN (°)	104.5	109.5	121.0	121.0
U1 to NA (°)	22.0	35.0	47.1	47.6
IMPA (°)	96.3	81.0	82.5	80.0
L1 to NB (°)	25.0	15.0	14.9	12.2
U1/L1 (°)	124.1	134.0	121.1	123.5
Upper lip (mm)	1.2	-5.8	-2.4	-4.1
Lower lip (mm)	2.0	-0.8	-2.0	-2.0

archwires with active omega loops and an open-coil spring were used for 3 months. The ectopic canine had a transposed root with the maxillary right first

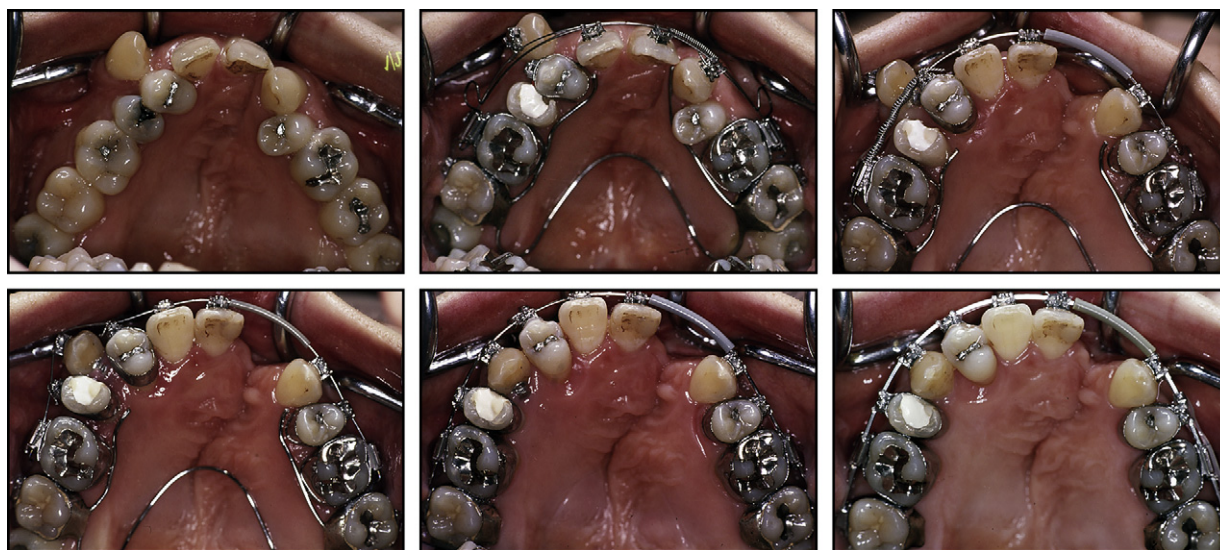


Fig 4. Intraoral maxillary occlusal photographs during treatment. Premaxillary segment has been gradually expanded, and the maxillary right first premolar was substituted for the lateral incisor. A Porter-type slow expansion appliance was used to expand the maxillary arch bilaterally. After carefully observing the response of the maxilla, full fixed appliances were placed in the maxillary arch to continue the expansion.

premolar. To reduce the treatment time and prevent additional root resorption of the canine, the maxillary right first premolar was substituted as a lateral incisor. Six months after beginning orthodontic treatment, 0.022-in tip-edge appliances were placed in the mandibular arch.

During the finishing stage, multi-loop edgewise archwires and Class III diagonal and up-and-down elastics were used to correct the dental midline and Class III canine relationship on the right side. At the detailing stage, the lingual surface of the maxillary right first premolar was reduced to establish a balanced occlusion. Also, recontouring of the prominent buccal ridge or a veneer was recommended for the premolar after orthodontic treatment. At this stage, the patient was referred to a restorative dentist to evaluate the space for the missing tooth (Fig 4).

Active treatment time was 25 months. After treatment, a pontic was fabricated and attached to the adjacent teeth. Because of the patient's high caries tendency and future restorations, maxillary and mandibular Essix retainers were delivered instead of fixed retainers. The patient was instructed to wear them 24 hours per day for 1 year and then at night only after 1 year. Recall visits for retainer checks occurred at 1, 3, and 6 months during the first year. To ensure continued satisfactory posttreatment alignment of the mandibular and maxillary anterior dentitions, the use of fixed or removable retainers was recommended indefinitely.¹³ At the end of the

orthodontic treatment, the patient was referred to her general dentist for restorative treatment and to a periodontist to correct the gingival margin discrepancies. Also, she was advised to visit an oral surgeon every 6 months for evaluation of the maxillary right and left third molars, and the mandibular left third molar.

TREATMENT RESULTS

The posttreatment records showed that the treatment objectives were achieved (Figs 5-8). The facial photographs showed improved profile esthetics (Fig 5). Class I canine and Class II molar relationships were established with a canine-protected occlusion. The maxillary intercanine width was significantly increased in the premaxillary region (before, after, and 6-year retention amounts were 23.26, 33.73, and 33.56 mm, respectively). The maxillary intermolar width was increased (before, after, and 6-year retention amounts were 28.25, 32.35, and 32.28 mm, respectively). The dental midlines were aligned with the facial midline, ideal overbite and overjet were achieved, and the curve of Spee was successfully leveled. The maxillary right central incisor needed more labial root torque after treatment, but it showed improvement at the 6-year follow-up (Fig 9).

The posttreatment lateral cephalometric analysis and superimposition showed significant skeletal changes with forward movement of the maxilla (ANB, -1.5° , Wits appraisal, -1.4 mm) and an increase in the mandibular plane angle (SN-MP, 38.0°). Proclination of the

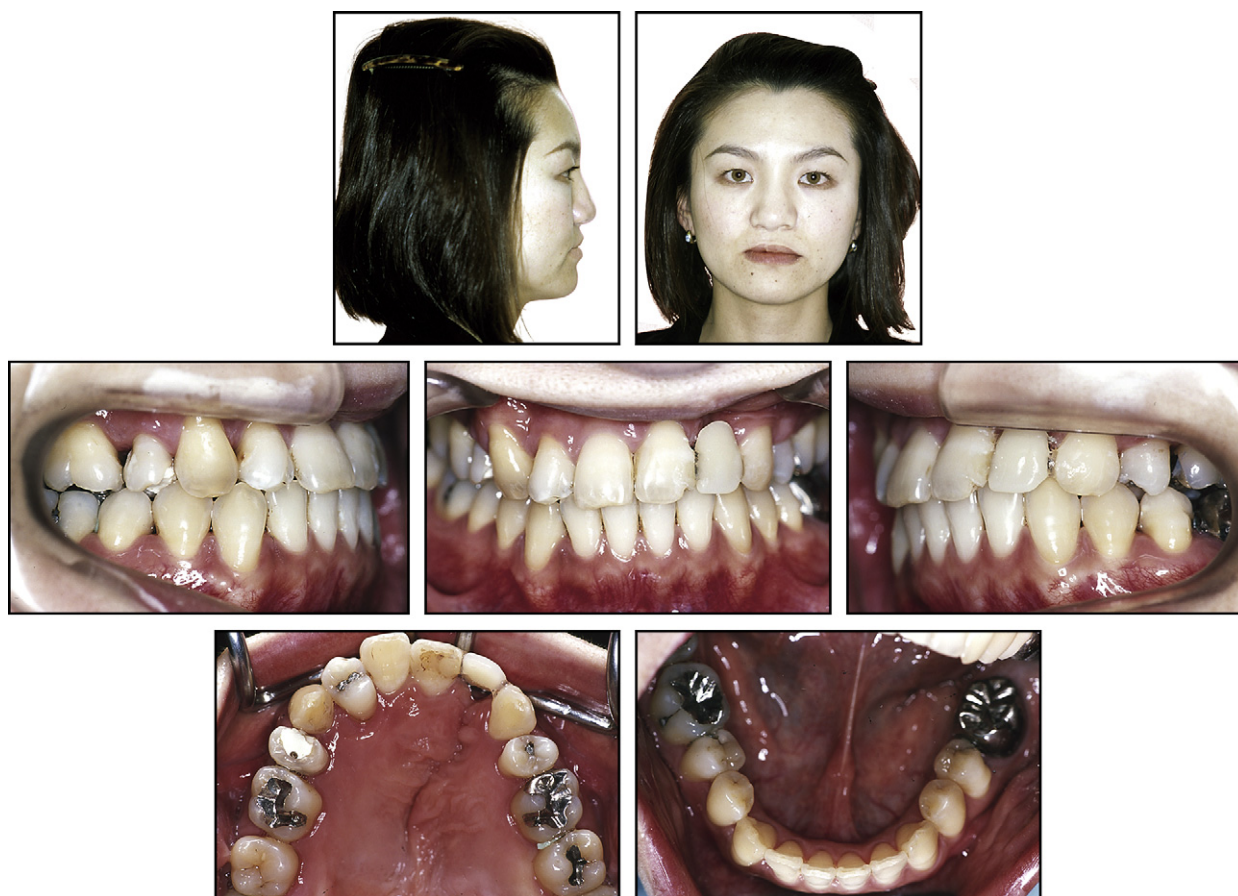

Fig 5. Posttreatment facial and intraoral photographs with a resin-bonded bridge.

incisors (U1 to SN, 121.0°) was also observed primarily in the maxillary incisors; this helped to correct the anterior crossbite. The inclination of the mandibular incisors was stable (IMPA, 82.5°) (Fig 7, A; Table). A posttreatment panoramic radiograph showed proper spacing and acceptable root parallelism for a potential future implant, with no signs of bone or root resorption (Fig 7, C). The patient's facial profile, especially her midface, was improved. Furthermore, the esthetic plane was improved primarily by decreasing the nasolabial angle (Fig 8). At the 6-year and 9-year follow-ups, the patient had a stable occlusion, with the results of the orthodontic treatment maintained (Figs 9 and 10). The radiographic examination showed fairly stable results (Fig 11).

DISCUSSION

Dental abnormalities are common in children with orofacial clefts. When compared with children without clefts, children with clefts often have abnormal numbers, sizes, and shapes of teeth. More often, at least 1 tooth is missing,^{3,14-16} or the sizes of the teeth are significantly

reduced.³ The incidence of morphologic irregularities is higher for all teeth, and the teeth on both sides of the cleft are often affected by enamel hypoplasia.¹⁷

Treatment of the residual alveolar defect in patients with cleft lip and palate generally requires bone grafting.¹⁸ If a bone graft is placed before the eruption of teeth adjacent to the cleft, it will improve the periodontal support of those teeth. Secondary or delayed alveolar bone grafting can be performed after primary lip repair.^{19,20} If a bone graft is done after the eruption of the canine, the bone will not improve the crestal height of support and resorb quickly to its original level.

Controversies concerning alveolar bone grafting require a rational and evidence-based approach. These controversies relate to the timing of the alveolar bone graft, the sequencing of orthodontic treatment to correct a transverse discrepancy with palatal expansion, and the sites and types of bone for the graft.^{21,22} Permanent canine root formation generally occurs between the ages of 8 and 11 years. Rarely is the graft placed before this time, although occasionally it can be

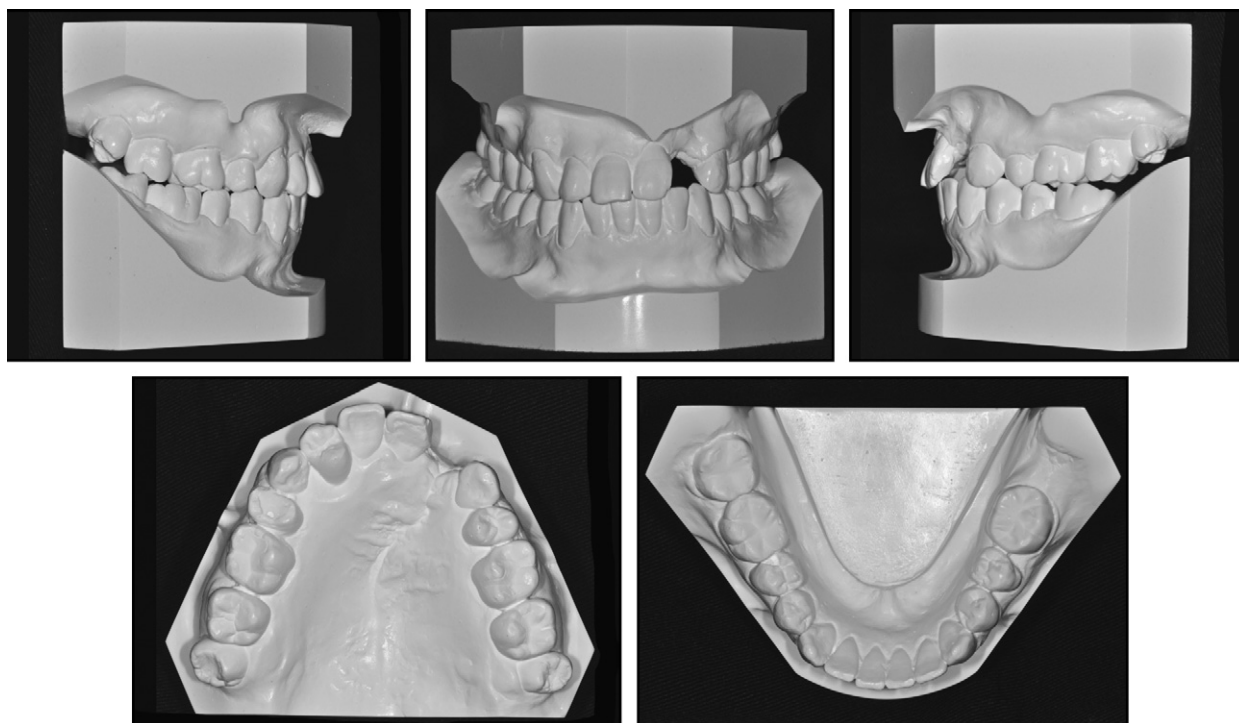


Fig 6. Posttreatment dental casts.

placed at an earlier age to improve the prognosis of a lateral incisor.

Once teeth have erupted into the cleft site, their periodontal support will not improve without a bone graft. Instead, the height of the crest of the alveolar bone resorbs to its original level. For this reason, performing the graft before the eruption of the permanent canine is recommended. If the lateral incisor is on the distal side of the cleft, the graft should be placed earlier. Results from primary bone grafting indicate an adverse effect on maxillary development, but, because maxillary growth is almost completed by 10 years of age, a secondary alveolar bone graft at this age should have a minimal, if any, effect on subsequent facial growth and development.

Alignment of the incisors adjacent to the cleft, which typically are rotated or tipped, is limited by the alveolar bone into which the roots of the teeth can be moved. If appliances have been placed preoperatively, orthodontic tooth movement should be delayed until 3 to 6 weeks after the bone graft. Early movement of the roots into grafted bone appears clinically to consolidate the alveolar bone and to improve crestal alveolar height. If the lateral incisors are malformed or absent, especially in patients with bilateral clefts, the canine is encouraged to erupt adjacent to the central incisors. Closing the

edentulous space is an advantage, thus avoiding the need for a prosthetic replacement of the absent lateral incisors. However, canine substitution needs to be considered in the context of the occlusion, the crown morphology, and the need for orthognathic surgery.

There isn't a consensus among dental clinicians about the treatment of dental transposition. If the transposed teeth are in the mandible, the lateral incisor will usually be extracted or an attempt will be made to align the teeth in their transposed configuration,²³⁻²⁵ but when maxillary canine and lateral incisor are transposed, correction is recommended for esthetic reasons.²⁶ In the case of the maxillary canine and first premolar, they can be maintained with the only potential issue being interferences from the palatal cusp of the premolar which should be minimized. Adjustment of the palatal cusp will typically require less treatment time than other options.²⁷⁻²⁹

In our patient, the deep mandibular curve of Spee was leveled by uprighting and tipping the posterior teeth back by using a multi-loop edgewise archwire with Class III elastics. The extrusion of the premolars and molars resulted in an increased mandibular plane, a compatible cant of the maxillary and mandibular occlusal planes, and downward and backward rotation of the mandible, which helped to correct the Class III skeletal relationship.

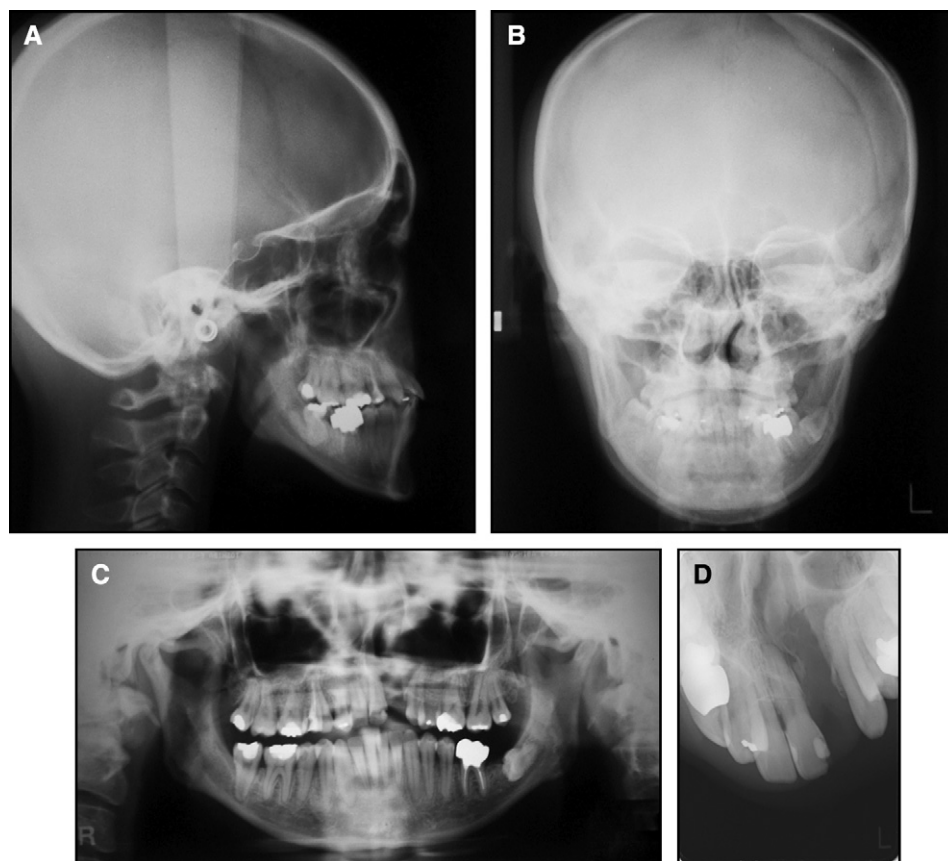


Fig 7. Posttreatment radiographs: **A**, lateral cephalogram; **B**, posteroanterior cephalogram; **C**, panoramic radiograph; **D**, occlusal radiograph. The posttreatment panoramic radiograph showed proper space opening and acceptable root parallelism for a potential future implant, with no signs of bone or root resorption.

The cephalometric analysis and prediction tracings provide further information for deciding whether a patient can be treated by orthodontics alone, or by orthodontics and an orthognathic surgical procedure. If the skeletal discrepancy is mild and esthetic concerns are minimal, dental compensation by orthodontic treatment alone might be recommended. A change in axial inclination of the teeth can camouflage the skeletal relationship adequately. However, one should be cautious in a growing patient, because he or she might outgrow the dental correction so that ultimately skeletal surgery would be indicated. The preoperative phase of orthodontic treatment requires decompensation of the dentition so that the maxillary and mandibular teeth are placed in their correct relationships relative to the underlying skeletal bases. If orthodontic therapy has achieved the ideal relationship of the teeth to the maxillary and mandibular skeletal bases, surgical movements will cause the

dentition and the maxilla and the mandible to be optimally related.

In young children, the benefit of distraction osteogenesis in a hypoplastic maxilla lies in a more gentle skeletal advancement with corticotomy cuts instead of a down-fracture of the maxilla. The orthodontist also can monitor for hypernasal speech that could occur with advancement of maxilla. Because the nasomaxillary complex is advanced slowly, at a millimeter per day, speech can be evaluated at intervals as advancement proceeds and adaptation of the velopharyngeal mechanism occurs.

The timing and sequencing of treatment require close collaboration among the team. The decision to delay surgical orthodontic treatment until growth is stabilized might be sound but not always in the patient's best interest, especially when psychosocial development is affected. In some instances, skeletal surgery could be

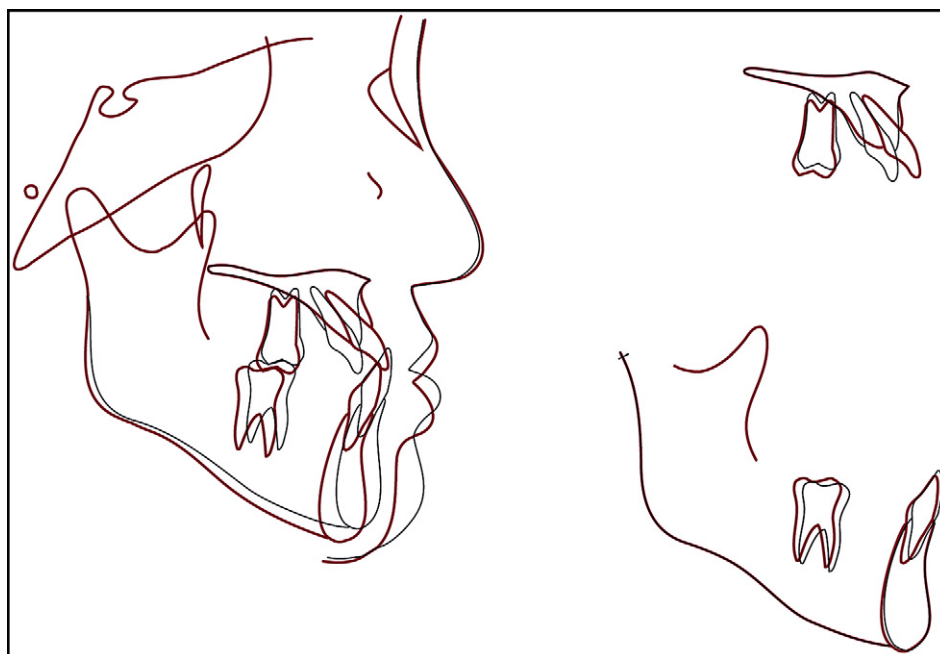


Fig 8. Cephalometric superimposition: *black line*, pretreatment; *red line*, posttreatment.

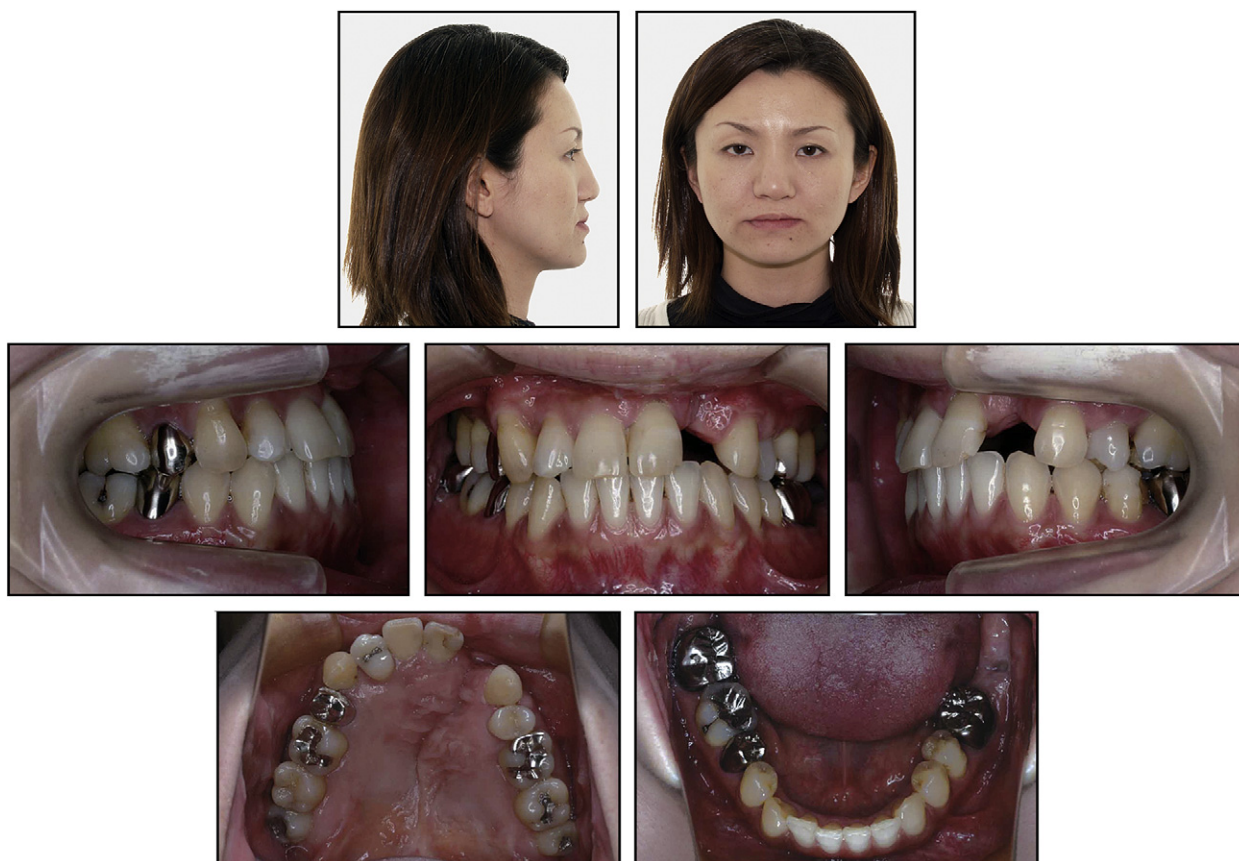

Fig 9. Six-year posttreatment facial and intraoral photographs.

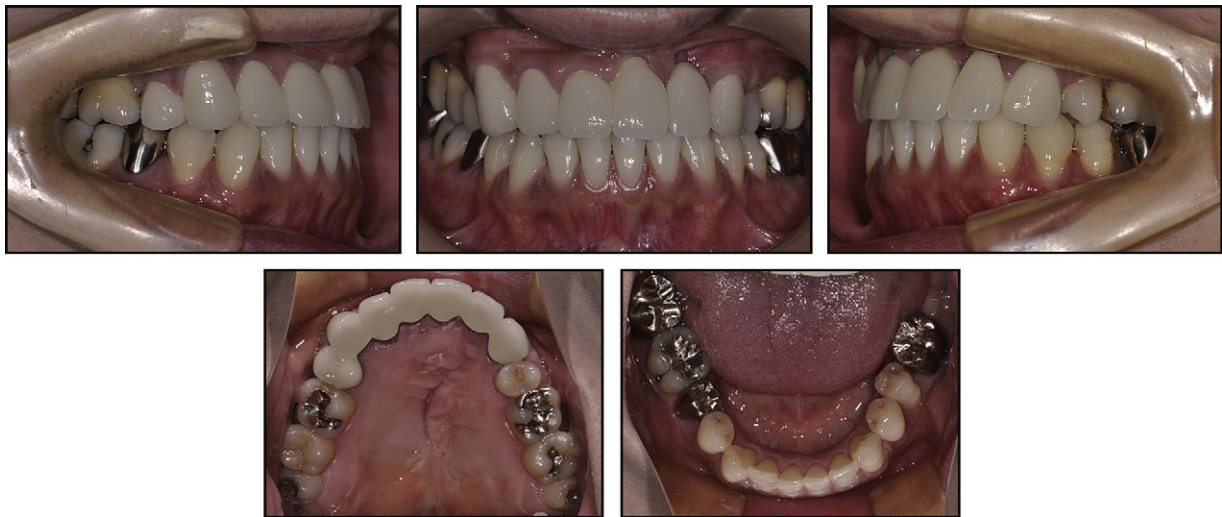

Fig 10. Nine-year posttreatment intraoral photographs.

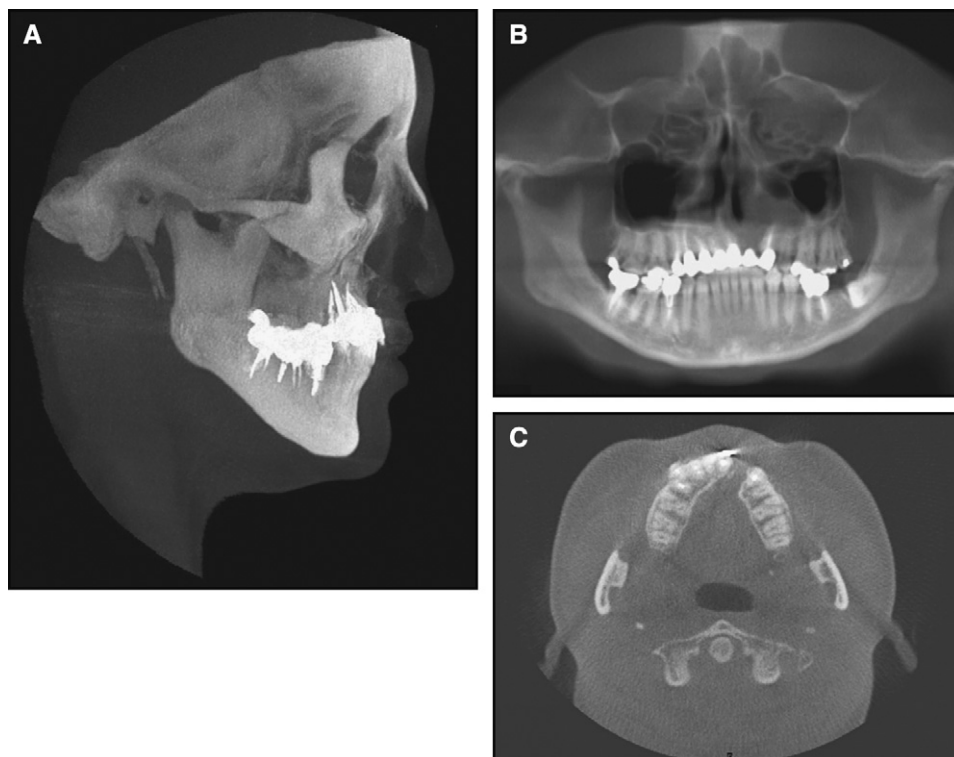


Fig 11. Nine-year posttreatment cone-beam computed tomography images: **A**, lateral maximum intensity projection image; **B**, curved planar reconstruction image; **C**, multiplanar reconstruction image.

indicated before growth is completed, knowing that another procedure might be necessary if the patient outgrows the correction. As a general rule, skeletal surgery, orthodontic intervention, and final prosthetic rehabilitation should be completed before final soft-tissue

revisions such as a rhinoplasty. The outcomes of soft-tissue surgical revisions, combined with osteotomies for the mobilization of the maxilla and the mandible, are often unpredictable until the skeletal discrepancy has been treated.

CONCLUSIONS

This patient's treatment was unconventional, but it was successful in significantly improving her masticatory function and smile, along with favorable dental and facial results. Although the appearance of the substituted maxillary right first premolar for the lateral incisor was not ideal, the generalized esthetics and function were significantly improved without surgery, and it was stable 9 years after appliance removal.

REFERENCES

- Ching GH, Chung CS. A genetic study of cleft lip and palate in Hawaii. I. Interracial crosses. *Am J Hum Genet* 1974;26:162-76.
- Berkowitz S. State of the art in cleft palate orofacial growth and dentistry. A historical perspective. *Am J Orthod* 1978;74:564-76.
- Olin WH. Dental anomalies in cleft lip and cleft palate patients. *Angle Orthod* 1964;34:119-23.
- Fishman LS. Factors related to tooth number, eruption time, and tooth position in cleft palate individuals. *ASDC J Dent Child* 1970;37:303-6.
- Ranta R, Tulensalo T. Symmetry and combinations of hypodontia in non-cleft and cleft palate children. *Scand J Dent Res* 1988;96:1-8.
- Kang JH, Kang JS, Son WS. A study of the frequency of congenital missing and supernumerary teeth in cleft lip and palate patients. *Korean J Orthod* 1993;23:319-26.
- Bok JK, Son WS. The effects of cleft on mesiodistal dimension of permanent teeth in unilateral cleft lip and palate patients. *Korean J Orthod* 1995;25:447-51.
- Vichi M, Franchi L. Abnormalities of the maxillary incisors in children with cleft lip and palate. *ASDC J Dent Child* 1995;62:412-7.
- Tsai TP, Huang CS, Huang CC, See LC. Distribution patterns of primary and permanent dentition in children with unilateral complete cleft lip and palate. *Cleft Palate Craniofac J* 1998;35:154-60.
- Ranta R. A review of tooth formation in children with cleft lip/palate. *Am J Orthod Dentofacial Orthop* 1986;90:11-8.
- Kim YH, Han UK, Lim DD, Serrano MP. Stability of anterior openbite correction with multiloop edgewise archwire therapy: a cephalometric follow-up study. *Am J Orthod Dentofacial Orthop* 2000;118:43-54.
- Sato S. Case report: developmental characterization of skeletal Class III malocclusion. *Angle Orthod* 1994;64:105-11.
- Little RM, Riedel RA, Årtun J. An evaluation of changes in mandibular anterior alignment from 10 to 20 years postretention. *Am J Orthod* 1988;93:423-8.
- Garn SM, Lewis AB, Kerewsky RS. Genetic, nutritional and maturational correlates of dental development. *J Dent Res* 1965;44:228-43.
- Weise W, Erdmann P. Anomalien der Zahnzahl und Zahnform im bleibenden Gebiss bei Lippen-Kiefer-Gaumen-Spalten. *Zahnärztl Rundsch* 1967;76:357-72.
- Ranta R. Comparison of tooth formation in noncleft and cleft-affected children with and without hypodontia. *ASDC J Dent Child* 1982;49:197-9.
- Kraus BS, Jordan RE, Pruzansky S. Dental abnormalities in the deciduous and permanent dentition of individuals with cleft lip and palate. *J Dent Res* 1966;45:1736-46.
- Witsenburg B. The reconstruction of anterior residual bone defects in patients with cleft lip, alveolus and palate. A review. *J Maxillofac Surg* 1985;13:197-208.
- Boyne PJ. Use of marrow-cancellous bone grafts in maxillary alveolar and palatal clefts. *J Dent Res* 1974;53:821-4.
- Boyne PJ, Sands NR. Combined orthodontic-surgical management of residual palato-alveolar cleft defect. *Am J Orthod* 1976;70:20-37.
- Vig KWL. Orthodontic considerations applied to craniofacial dysmorphology. *Cleft Palate J* 1990;27:141-5.
- Zins JE, Whittaker LA. Membranous vs endochondral bone autografts: implications for craniofacial reconstruction. *Surg Forum* 1979;30:521-3.
- Shapira Y. Bilateral transposition of mandibular canines and lateral incisors: orthodontic management of a case. *Br J Orthod* 1978;5:207-9.
- Shapira Y, Kuflinec MM. Orthodontic management of mandibular canine-incisor transposition. *Am J Orthod* 1983;83:271-6.
- Doruk C, Babacan H, Bicakci A. Correction of a mandibular lateral incisor-canine transposition. *Am J Orthod Dentofacial Orthop* 2006;129:65-72.
- Shapira Y, Kuflinec MM. Maxillary canine-lateral incisor transposition-orthodontic management. *Am J Orthod Dentofacial Orthop* 1989;95:439-44.
- Peck S, Peck L. Classification of maxillary tooth transpositions. *Am J Orthod Dentofacial Orthop* 1995;107:505-17.
- Shapira Y, Kuflinec MM. A unique treatment approach for maxillary canine-lateral incisor transposition. *Am J Orthod Dentofacial Orthop* 2001;119:540-5.
- Kuroda S, Kuroda Y. Nonextraction treatment of upper canine-premolar transposition in an adult patient. *Angle Orthod* 2005;75:472-7.